



## Case Report

# ClearPath aligners: An invisible approach for the correction of anterior open bite

Waqas Wahab\* and Tahir Mahmood

Dental Surgeon, Defence Dental &amp; Aesthetic Center, Lahore, Pakistan

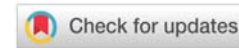
**Received:** 22 January, 2024  
**Accepted:** 06 February, 2024  
**Published:** 07 February, 2024

**\*Corresponding author:** Waqas Wahab, Dental Surgeon, Defence Dental & Aesthetic Center, Lahore, Pakistan, E-mail: [researchdevelopment098@gmail.com](mailto:researchdevelopment098@gmail.com)

**Keywords:** Clear aligners; Anterior open bite; Orthodontic treatment

**Copyright License:** © 2024 Wahab W, et al. This is an open-access article distributed under the terms of the Creative Commons Attribution License, which permits unrestricted use, distribution, and reproduction in any medium, provided the original author and source are credited.

<https://www.peertechzpublications.org>



## Abstract

Clear aligner treatment has established itself as a reputable orthodontic procedure known for its aesthetic appeal and comfort, particularly favored by adult patients. This case report details the clear aligner treatment administered to an adult patient presenting with an anterior open bite and spaced upper dentition. The treatment involved closing spaces and retracting upper anterior teeth, while interproximal reduction was performed in the lower arch. The Elastic Button Technique (EBT) was employed to address the open bite. A total of 9 sets of clear aligners were provided, with a recommended wear time of 22 hours per day for 10 days, spanning a four-month period. Consequently, this case study underscores the effectiveness of using clear aligners in orthodontic treatment to resolve anterior open bite issues. The inconspicuous design of these aligners not only contributes to enhanced periodontal health but also boosts patient acceptance.

## Introduction

In recent times, there has been a noticeable increase in the number of adults seeking orthodontic treatment, expressing a preference for aesthetic and more comfortable alternatives compared to traditional fixed orthodontic appliances. The concept of transparent orthodontic appliances was first introduced by Kesling in 1946. He developed the theory of using a series of thermoplastic dental aligners to gradually move misaligned teeth to improved positions [1-3]. In 1997, Align Technology, headquartered in Santa Clara, California, made a significant contribution to orthodontics by introducing advanced 3D imaging technology, leading to the launch of Clear Aligner Therapy (CAT). This innovation essentially evolved Kesling's original concept into a practical orthodontic treatment option. Since then, CAT has established itself as a reputable orthodontic procedure known for its aesthetic appeal and comfort, particularly favored by adult patients [4].

Initially, aligner therapy was utilized to address minor crowding or close diastemas. However, advancements in aligner materials, attachment designs, and 3D software have

expanded their applicability, enabling the treatment of various malocclusions [5]. Among the challenges faced by orthodontists, managing anterior open bite has proven particularly intricate [6]. This condition, characterized by insufficient vertical arch contact due to poor dental and/or skeletal positioning resulting in improper occlusion, necessitates tailored treatment based on its specific etiology. Treatment options encompass maxillofacial surgery for skeletal-origin open bite, intrusion of posterior segments to address over-eruption of posterior teeth, or extrusion of the anterior dental segment, especially in cases with inadequate vertical development in the premaxillary region [7].

This case study outlines the application of clear aligners to rectify an anterior open bite in an adult patient. It chronicles the treatment process, advancements made, and the ultimate outcomes of this particular orthodontic intervention in addressing the stated issue. The report is expected to provide insights into the treatment plan, the application of clear aligners, the patient's response to the treatment, any challenges faced during the process, and, most importantly, the effectiveness of the treatment in resolving the malocclusion.

## Case report

A 22-year-old female patient visited our facility, expressing concerns about an anterior open bite and spacing in her upper dentition. Her medical history was uneventful, with no reported familial or dental issues. Upon extraoral examination, we noted a dolichocephalic head shape, leptoprosopic face form, symmetrical frontal view, orthognathic profile, medium nose, and competent lips (Figure 1). The interlabial gap fell within the average range. The temporomandibular joint was examined by bilateral manipulation technique, and there were no reported symptoms or issues.

During the smile analysis, we observed adequate incisor display, although the alignment of the teeth was not optimal. The smile arc was non-consonant with the lower lip curvature. Intraoral examination revealed a class I malocclusion with fair oral hygiene and an average periodontal status. Both molars and canines displayed class I relationships. The overjet measured 3 mm with a dental anterior open bite of 4mm, and coincident midlines were observed.

The upper arch showed constriction with spaced dentition, while the lower arch exhibited mild crowding. A panoramic radiograph confirmed a healthy periodontal condition without cavities, root resorption, or any dental abnormalities. Cephalometric analysis indicated a skeletal Class I relationship and a normodivergent facial pattern with bimaxillary proclination.

## Treatment objectives

The primary goal of the orthodontic treatment involved the correction of anterior open bite through the use of clear aligners by retraction and extrusion of upper and lower dentition. Additional objectives included leveling, alignment, space closure, and posterior dental expansion of the upper arch.

## Treatment options

We examined various treatment possibilities with the patient, taking into account the following:

- The initial option involved conventional braces for orthodontic treatment, but the patient declined this choice, expressing a preference for a visually appealing appliance.
- The second alternative included the utilization of clear aligners, aligning with the patient's desire for a more aesthetically pleasing solution.

## Treatment procedure

Following the examination and history-taking, we proceeded to capture intraoral and extraoral photographs, along with intraoral scans using an intraoral scanner. These records were then sent to the ClearPath facility for the development of a personalized treatment plan.

The panoramic X-ray confirmed the presence of sufficient bone structure and indicated average oral hygiene, fulfilling

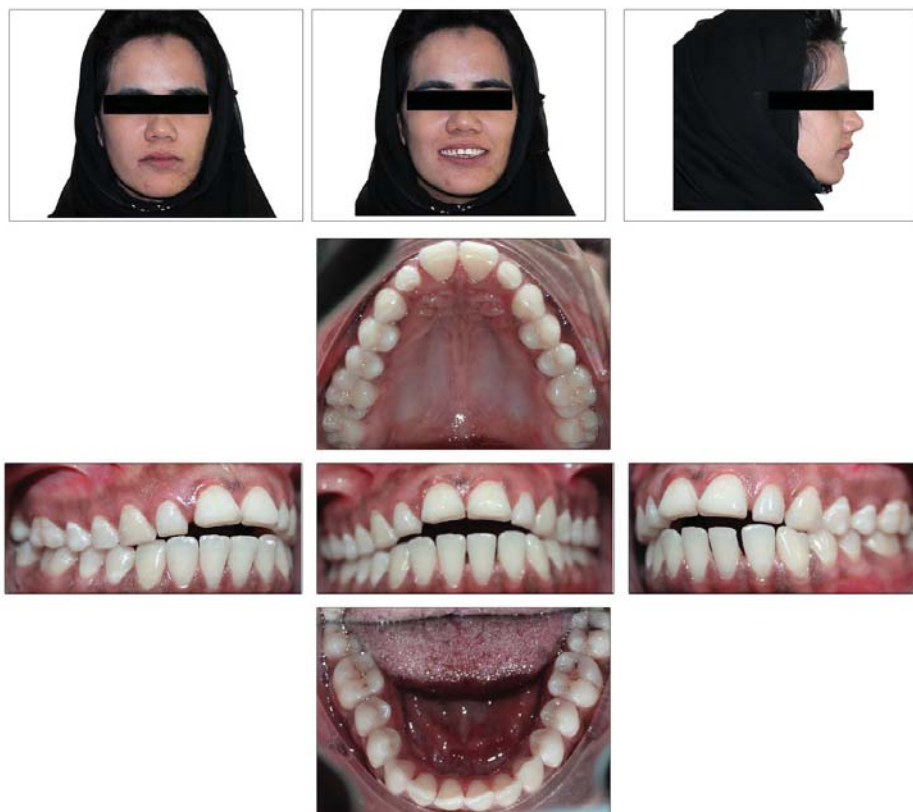


Figure 1: Pre-treatment; extraoral & intraoral photographs.

the essential requirements for orthodontic treatment. No additional dental procedures were needed, making the case suitable for clear aligner treatment to proceed.

After the record submission, a 3D treatment plan consisting of 09 stages in both arches was generated. The approach involved non-extraction, with complete space closure in the upper arch and Interproximal Reduction (IPR) in the lower arch. A treatment simulation (Figure 2) was presented to the patient for her review, and upon her satisfaction, approval was granted.

Within 7 days of submitting the records, the treatment plan was discussed with the patient. The patient expressed a high level of satisfaction with the proposed plan, and no modifications were required. A total treatment duration of 4 months was recommended and readily approved by the patient. Subsequently, the treatment commenced shortly thereafter.

**IPR technique:** Interproximal Reduction (IPR) is a method involving the precise removal of a thin layer of enamel between adjacent teeth to alleviate crowding [8]. Various techniques for IPR exist, such as the use of burs, discs, and abrasive strips [9]. In this particular investigation, thin diamond-coated double-sided abrasive strips were employed for IPR. The procedure was carefully measured using an IPR gauge, and afterward, topical fluoride was applied to prevent any potential adverse effects.

**EBT technique:** The Elastic Button Technique (EBT) is employed in clear aligner therapy to address particular orthodontic issues by affixing small buttons to specific teeth and utilizing elastics to exert force between them. This force aids in repositioning the teeth to the desired alignment [10].

In this case, stainless steel buttons were securely bonded to the buccal surfaces of the upper central and lower central incisors, enabling extrusion movements to successfully close the open bite.

### Treatment progress

Upon approval of the treatment simulation, we obtained the IPR and MRF forms (Figures 3,4) from the aligner facility, accompanied by 9 sets each of upper and lower aligners. The recommended wear duration for each set was 22 hours per day for a span of 10 days. The patient received comprehensive guidance regarding oral hygiene and periodontal health. Initially, the patient received the initial set of aligners and was scheduled for an IPR appointment before progressing to the second set. IPR was conducted in the lower arch at two specific points, resulting in a bilateral reduction of 0.6 mm between the canines and lateral incisors.

Stainless steel buttons were affixed to the upper and lower central incisors before the subsequent batch of aligners was provided. For extrusion movements, 3/16 elastics (medium) were recommended, with a suggested wear time of 18 hours. Subsequently, the patient received successive sets of aligners and underwent evaluations of periodontal health and aligner tracking every three months, consistently yielding satisfactory results. The patient demonstrated commendable compliance, leading to the successful completion of the treatment.

Upon completion of the treatment, two sets of retainers were issued. The patient was instructed to wear them full-time for the initial six months, followed by night-time wear for three months, and then transitioning to alternate night-time wear for the remaining three months.

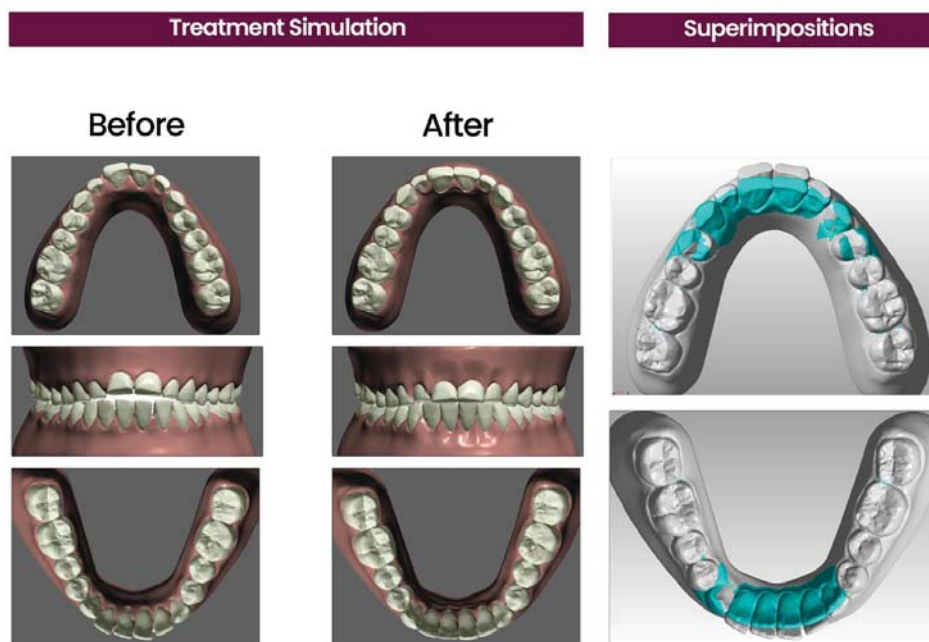


Figure 2: 3D treatment plan (a) Before & After, (b) Superimpositions.

## Treatment Diagram

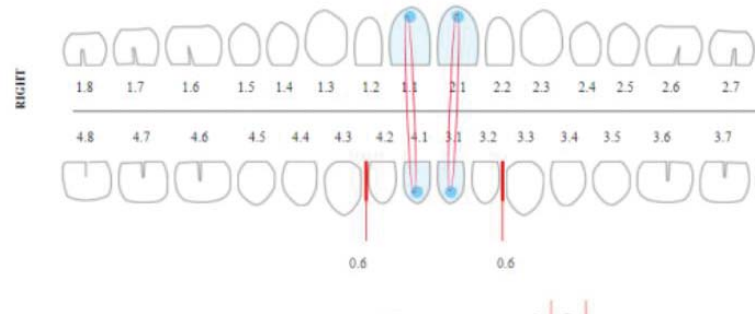


Figure 3: Interproximal reduction form.

Stg. #	Upper Right								Upper Left							
	1	2	3	4	5	6	7	8	9	10	11	12	13	14	15	16
1																
2								LTP	LTP							
3						BTP					BTP					
4				MTP	MTP					MTP	MTP					
5				DRO	MTP						DRO					
6				DRO				LTP	LTP			DRO				
7							DTP	LTP	LTP	DTP						
8							DTP	LTP	LTP	DTP						
9						LTP	LTP	LTP	LTP	LTP	LTP					

Stg. #	Lower Right								Lower Left							
	32	31	30	29	28	27	26	25	24	23	22	21	20	19	18	17
1																
2								LTP			DTP					
3								LTP		DTP						
4								LTP	DRO							
5								LTP	LTP	DRO						
6								LTP	LTP	LTP	LTP					
7								LTP	LTP	LTP	LTP					
8							LTP	LTP	LTP	LTP	LTP	LTP				
9							LTP	LTP	LTP	LTP	LTP	LTP				

\*Please use EBT on specific tooth/teeth ONLY at the particular stage mentioned in MRF form.  
 \*EBT technique has to be used wherever "EXT" code is written.

Code	Movement Detail	Code	Movement Detail	Code	Movement Detail
MTR	Mesial Translation	MTP	Mesial Tipping	DTO	Distal Torque
DTR	Distal Translation	DTP	Distal Tipping	MTO	Mesial Torque
LTR	Lingual Translation	BTP	Buccal Tipping	INT	Intrusion
BTR	Buccal Translation	BTO	Buccal Torque	EXT	Extrusion
LTP	Lingual Tipping	LTO	Lingual Torque	DRO	Distal Rotation
				MRO	Mesial Rotation

Figure 4: Movement Record Form.

### Treatment result

The entire treatment duration extended over 4 months, during which each aligner was worn for a significant 22 hours per day and replaced every 10 days. At the conclusion of this treatment, successful resolution of spacing, anterior open bite, and proclination of the anterior teeth was achieved. This resulted in the establishment of an ideal overjet and overbite, ensuring proper alignment and bite function (Figure 5).

Moreover, the treatment culminated in the harmonious centering of both the maxillary and mandibular arches, contributing to improvements in both the esthetic and functional aspects of the patient's smile. Importantly, periodontal health was meticulously preserved throughout the treatment, with no indications of gum recession or the development of periodontal pockets, thereby safeguarding the overall well-being of the patient's oral health.



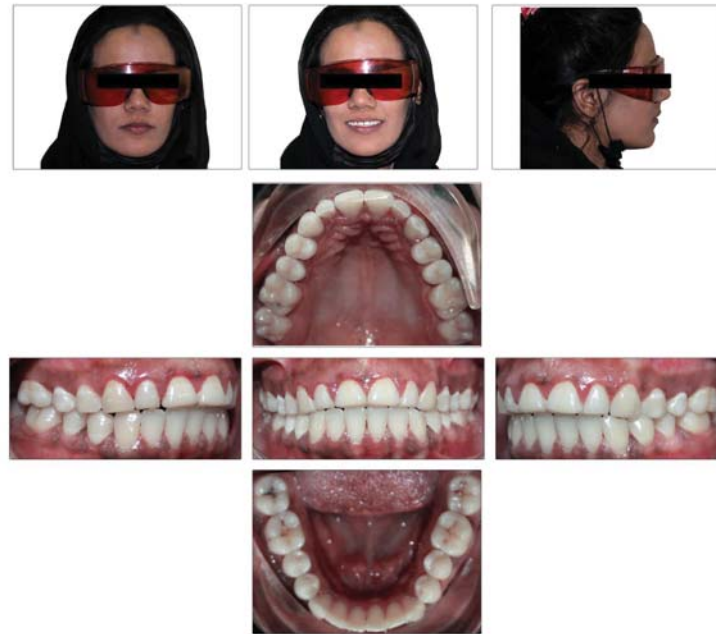


Figure 5: Post-treatment records; extra-oral and intra-oral photographs.

## Discussion

The aim of this study was to evaluate the reliability of clear aligners in the treatment of anterior open bite using a non-extraction treatment-based approach.

Prior studies have indicated that the origin of an anterior open bite is intricate and involves a combination of genetic and environmental factors, such as unfavorable growth patterns, parafunctional habits, airway issues, TMJ disorders, and early loss of primary teeth [11,12]. Distinguishing between these factors can be challenging. Therefore, an accurate diagnosis and identification of causative factors serve as essential guides in establishing appropriate objectives, devising ideal treatment plans, and implementing definitive corrective procedures [13]. Achieving stability in the treatment of anterior open bite is a critical consideration, as relapse or the return of the malocclusion can occur if proper measures are not taken. Several factors influence the stability of anterior open bite treatment including adequate retention, good compliance, and continuous follow-ups.

In this particular instance involving an anterior open bite, moderate spacing, and bimaxillary proclination, clear aligners were effectively utilized over a period of 4 months. Closure of spaces in the upper arch and retraction of anterior teeth were achieved, while Interproximal Reduction (IPR) was performed in the lower arch to address crowding. Up to 4 mm of total extrusion (absolute + relative) was achieved in the anteriors (Figure 6) A total of 9 sets of aligners were provided for both the upper and lower arches. Although alternative treatment options were presented to the patient, they chose clear aligners due to their discreet, hygienic, and comfortable attributes. Clear aligners offer a distinctive treatment approach for adult orthodontic patients, addressing aesthetic concerns, promoting

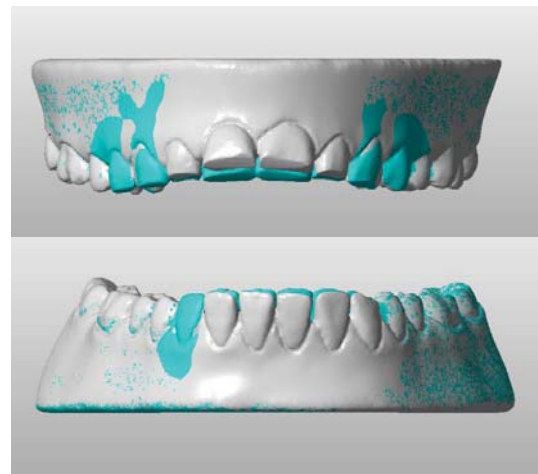


Figure 6: Overlay of extrusion movements.

hygiene, and addressing metal allergy issues while providing a treatment duration comparable to traditional fixed appliances [14].

In the context of clear aligner treatment, ensuring patient compliance holds the utmost significance. Patient education plays a pivotal role as a motivational tool, influencing the acceptance of the appliance and enhancing compliance [15,16]. In this particular case, the patient's active participation and communication with their clinician played a substantial role in the success of the treatment. The patient actively engaged with the 3D setup software, which visually depicted the expected tooth movement and progress throughout the treatment. This highlights the software's importance as an educational tool, effectively illustrating the final treatment objectives to the patient.

However, it is essential to acknowledge that the clear aligner system has its limitations [17]. It may exhibit less predictability in cases involving severe derotations, complex extrusions, or significant translations, potentially requiring additional treatment modalities [14]. Despite the potential for higher laboratory fees compared to conventional appliances, the virtual treatment setup, user-friendly nature, and high patient acceptance often outweigh the additional cost. This setup not only aids in diagnosis but also functions as an educational tool for patients. Moreover, patient cooperation remains critical for the overall success of the treatment, and in this case, it was excellent owing to the patient's enthusiasm for the process.

## Conclusion

In conclusion, this case study highlights the effectiveness of using clear aligners in orthodontic treatment to address anterior open bites. The inconspicuous design of these aligners not only promotes periodontal health but also contributes to higher patient acceptance. Additionally, the precise control over orthodontic movements, coupled with minimal risk of anchorage loss, renders it a compelling choice for clinicians in the management of such malocclusions.

## Consent & conflict of interest

A written consent form was signed by the patient for use of the dental records for publications & social media marketing. Also, there is no conflict of interest with this paper.

## References

- Kesling HD. Coordinating the predetermined pattern and tooth positioner with conventional treatment. *Am J Orthod Oral Surg.* 1946 May; 32:285-93. doi: 10.1016/0096-6347(46)90053-1. PMID: 21027613.
- Melsen B. Northcroft lecture: how has the spectrum of orthodontics changed over the past decades? *J Orthod.* 2011 Jun;38(2):134-43; quiz 145. doi: 10.1179/14653121141362. PMID: 21677105.
- Rosvall MD, Fields HW, Ziuchkovski J, Rosenstiel SF, Johnston WM. Attractiveness, acceptability, and value of orthodontic appliances. *Am J Orthod Dentofacial Orthop.* 2009 Mar;135(3): 276.e1-12; discussion 276-7. doi: 10.1016/j.ajodo.2008.09.020. PMID: 19268820.
- Ali SA, Miethke HR. Invisalign, an innovative invisible orthodontic appliance to correct malocclusions: advantages and limitations. *Dent Update.* 2012 May;39(4):254-6, 258-60. doi: 10.12968/denu.2012.39.4.254. PMID: 22774688.
- Patterson BD, Foley PF, Ueno H, Mason SA, Schneider PP, Kim KB. Class II malocclusion correction with Invisalign: Is it possible? *Am J Orthod Dentofacial Orthop.* 2021 Jan;159(1):e41-e48. doi: 10.1016/j.ajodo.2020.08.016. Epub 2020 Nov 19. PMID: 33223374.
- Subtelny JD, Sakuda M. Open-bite: diagnosis and treatment. *American journal of orthodontics.* 1964; 50(5):337-358.
- Savignano R, Valentino R, Razionale AV, Michelotti A, Barone S, D'Antò V. Biomechanical Effects of Different Auxiliary-Aligner Designs for the Extrusion of an Upper Central Incisor: A Finite Element Analysis. *J Healthc Eng.* 2019 Aug 7; 2019:9687127. doi: 10.1155/2019/9687127. PMID: 31485303; PMCID: PMC6702849.
- Meredith L, Li M, Cannon RD, Farella M. Interproximal reduction in orthodontics: why, where, how much to remove? *Aust Orthod J.* 2017; 33(2):150.
- Lapenaite E, Lopatiene K. Interproximal enamel reduction as a part of orthodontic treatment. *Stomatologija.* 2014;16(1):19-24. PMID: 24824056.
- Pariyatdulapak N, Churnjitapirom P, Srihirin T, Viwattanatipa N. Bond strength of orthodontic buttons on clear aligner materials. *Orthodontic Waves.* 2021; 80:4:224-231.
- Fujiki T, Inoue M, Miyawaki S, Nagasaki T, Tanimoto K, Takano-Yamamoto T. Relationship between maxillofacial morphology and deglutitive tongue movement in patients with anterior open bite. *Am J Orthod Dentofacial Orthop.* 2004 Feb;125(2):160-7. doi: 10.1016/j.ajodo.2003.03.009. PMID: 14765053.
- Rijpstra C, Lisson JA. Etiology of anterior open bite: a review. *J Orofac Orthop.* 2016 Jul;77(4):281-6. English. doi: 10.1007/s00056-016-0029-1. Epub 2016 Apr 20. PMID: 27098640.
- Matsumoto MA, Romano FL, Ferreira JT, Valério RA. Open bite: diagnosis, treatment and stability. *Braz Dent J.* 2012;23(6):768-78. doi: 10.1590/s0103-64402012000600024. PMID: 23338275.
- Boyd RL, Miller RS, Vlaskalic V. The Invisalign system in adult orthodontics: mild crowding and space closure cases. *J Clin Orthod.* 2020; 34:203-213.
- Sergl HG, Klages U, Zentner A. Pain and discomfort during orthodontic treatment: causative factors and effects on compliance. *Am J Orthod Dentofacial Orthop.* 1998 Dec;114(6):684-91. doi: 10.1016/s0889-5406(98)70201-x. PMID: 9844209.
- Harris K, Ojima K, Dan C, Upadhyay M, Alshehri A, Kuo CL, Mu J, Uribe F, Nanda R. Evaluation of open bite closure using clear aligners: a retrospective study. *Prog Orthod.* 2020 Aug 24;21(1):23. doi: 10.1186/s40510-020-00325-5. PMID: 32830306; PMCID: PMC7443419.
- Rask H, English JD, Colville C, Kasper FK, Gallerano R, Jacob HB. Cephalometric evaluation of changes in vertical dimension and molar position in adult non-extraction treatment with clear aligners and traditional fixed appliances. *Dental Press J Orthod.* 2021 Sep 10;26(4):e2119360. doi: 10.1590/2177-6709.26.4.e2119360.oar. PMID: 34524380; PMCID: PMC8439186.

Discover a bigger Impact and Visibility of your article publication with Peertechz Publications

### Highlights

- ❖ Signatory publisher of ORCID
- ❖ Signatory Publisher of DORA (San Francisco Declaration on Research Assessment)
- ❖ Articles archived in worlds' renowned service providers such as Portico, CNKI, AGRIS, TDNet, Base (Bielefeld University Library), CrossRef, Scilit, J-Gate etc.
- ❖ Journals indexed in ICMJE, SHERPA/ROMEO, Google Scholar etc.
- ❖ OAI-PMH (Open Archives Initiative Protocol for Metadata Harvesting)
- ❖ Dedicated Editorial Board for every journal
- ❖ Accurate and rapid peer-review process
- ❖ Increased citations of published articles through promotions
- ❖ Reduced timeline for article publication

Submit your articles and experience a new surge in publication services  
<https://www.peertechzpublications.org/submit>

Peertechz journals wishes everlasting success in your every endeavours.